

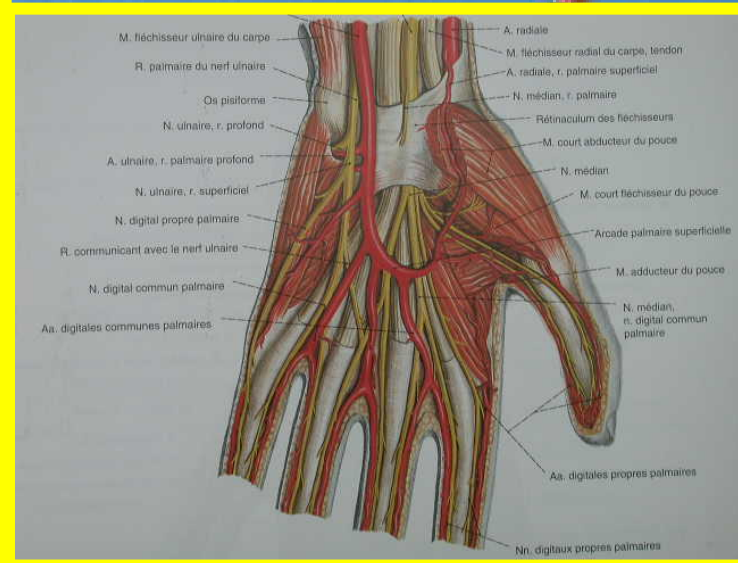
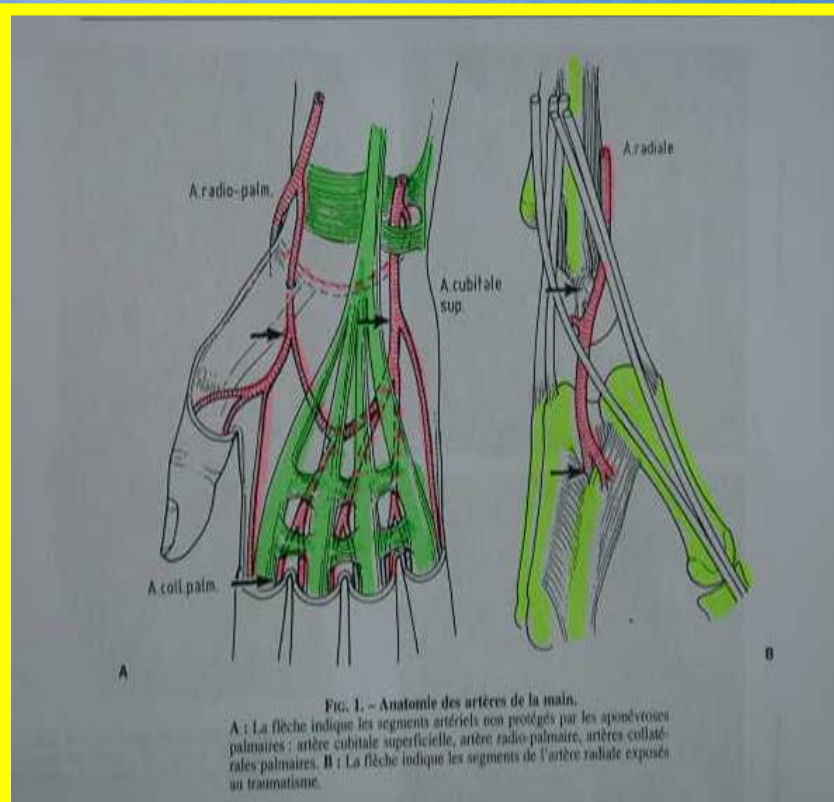
ROLLER, SKATE-BOARD AND ACUTE DIGITAL ISCHEMIA



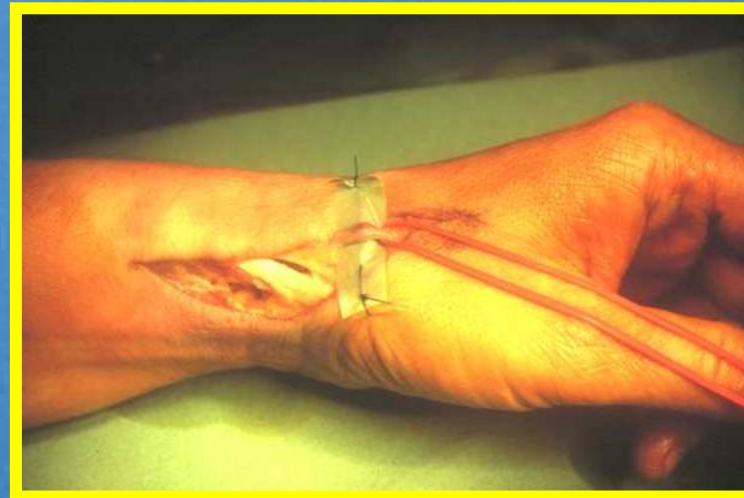
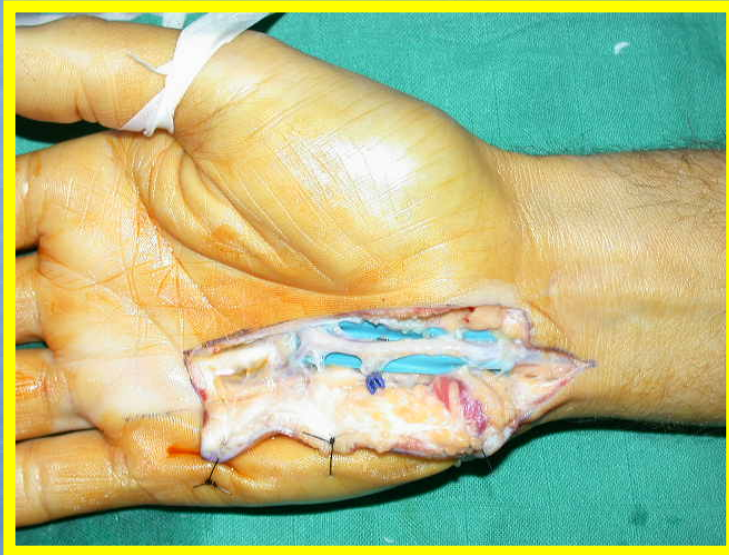M. SCHOofs
C. DOS REMEDIOS
P. LEPS
S. HOUZE
G. AUVRAY
Unité chirurgicale du Membre
Supérieur
Lammersart - Lille



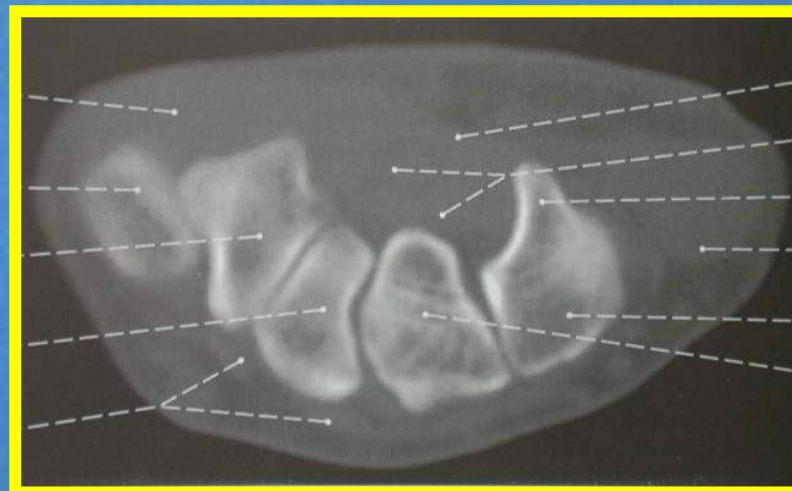
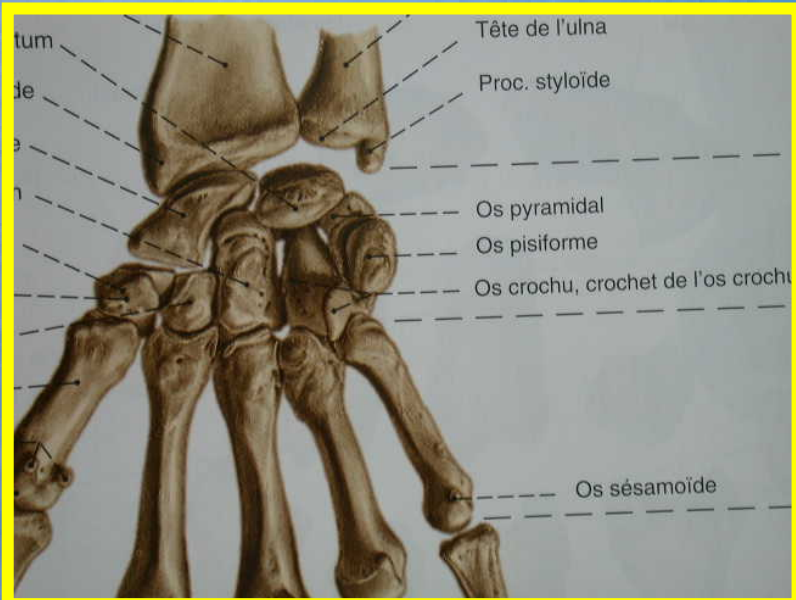
PHYSIOPATHOLOGY



PHYSIOPATHOLOGY



PHYSIOPATHOLOGY



CASE N° 1

- Boy, 14 years old
- Skate board
- Left hand
- Acute post traumatic ischemia of the 4th and 5th fingers



Case N° 2

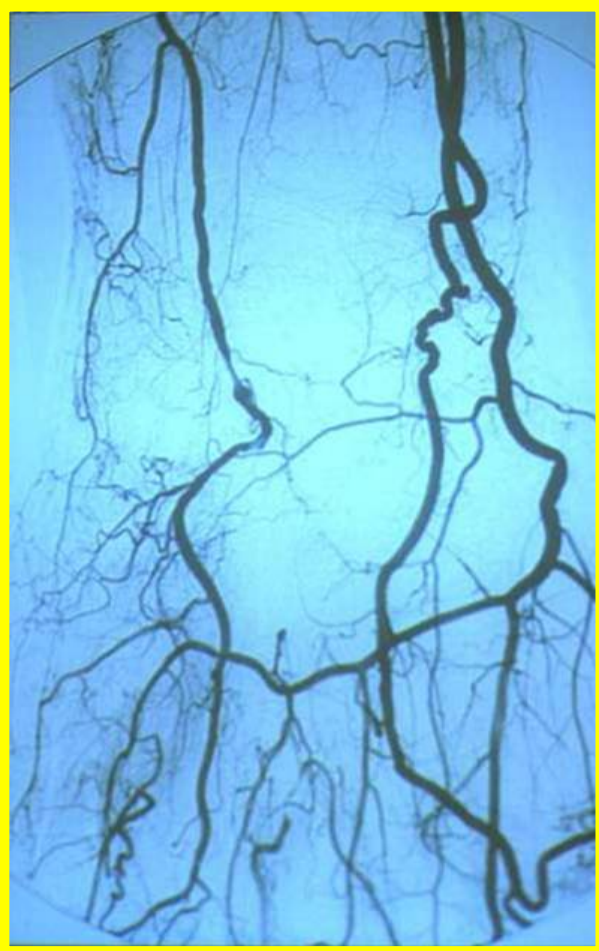- Man, 17 years old
- Roller
- Right hand
- Acute post traumatic ischemia of the 3rd, 4th, 5th fingers



For both cases :

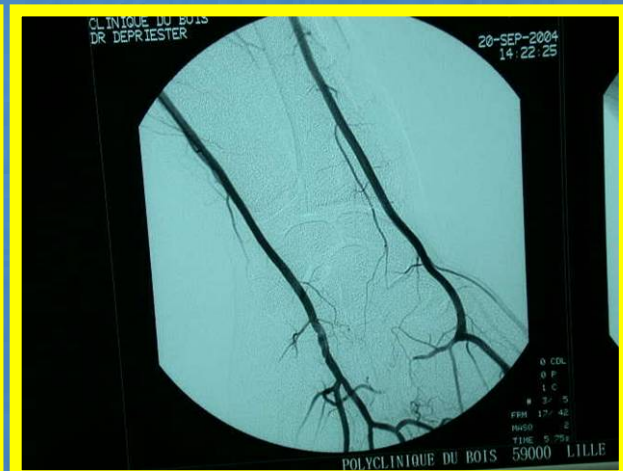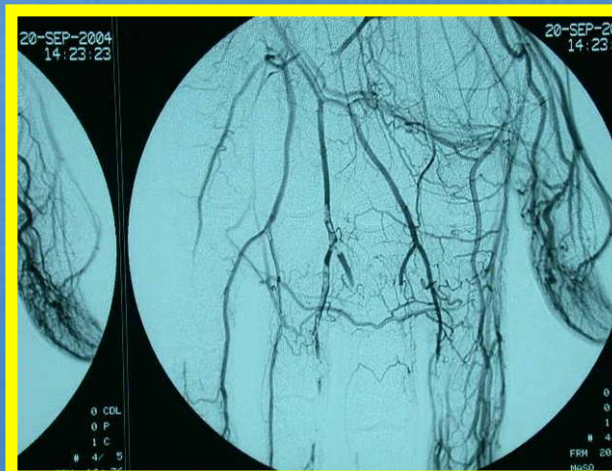- Diagnosis
 - Trauma
 - Acute ischemia
 - Pain
 - Oedema
 - X ray : no fracture of the triquetrum
 - Echo-doppler : confirmation of thrombosis





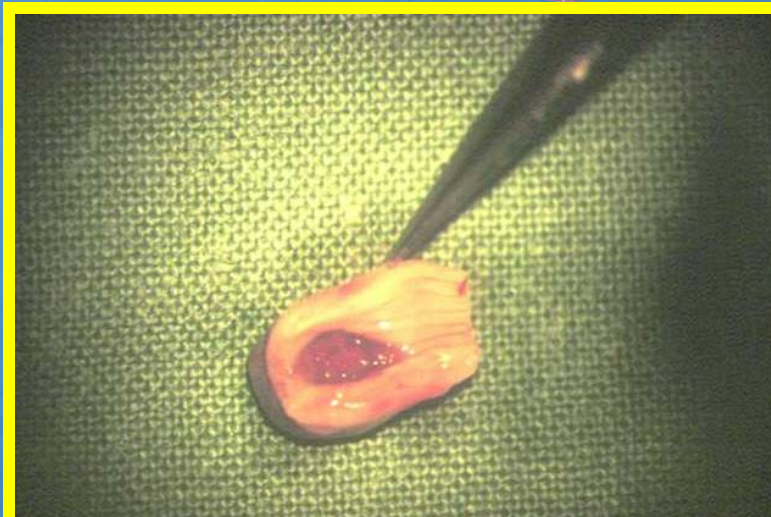
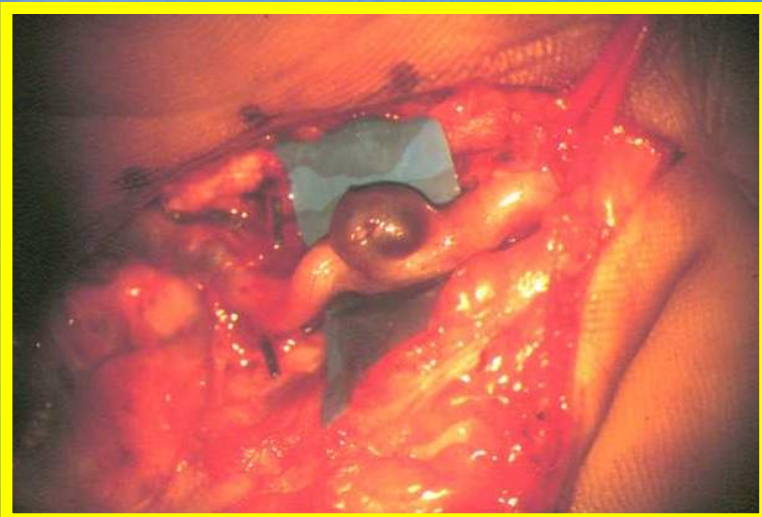
For both cases :

Angiography, localisation and extension
to digital arteries ?

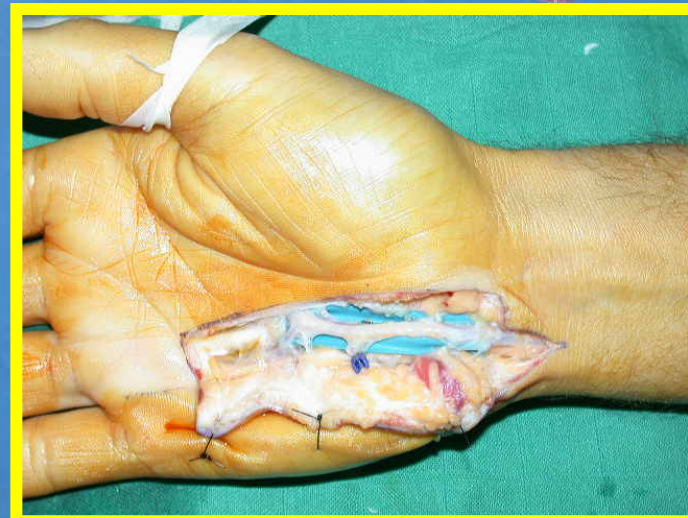
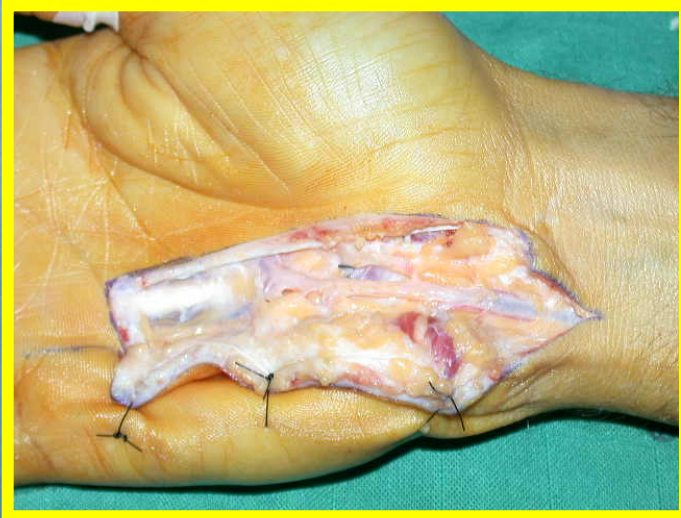
For both cases :

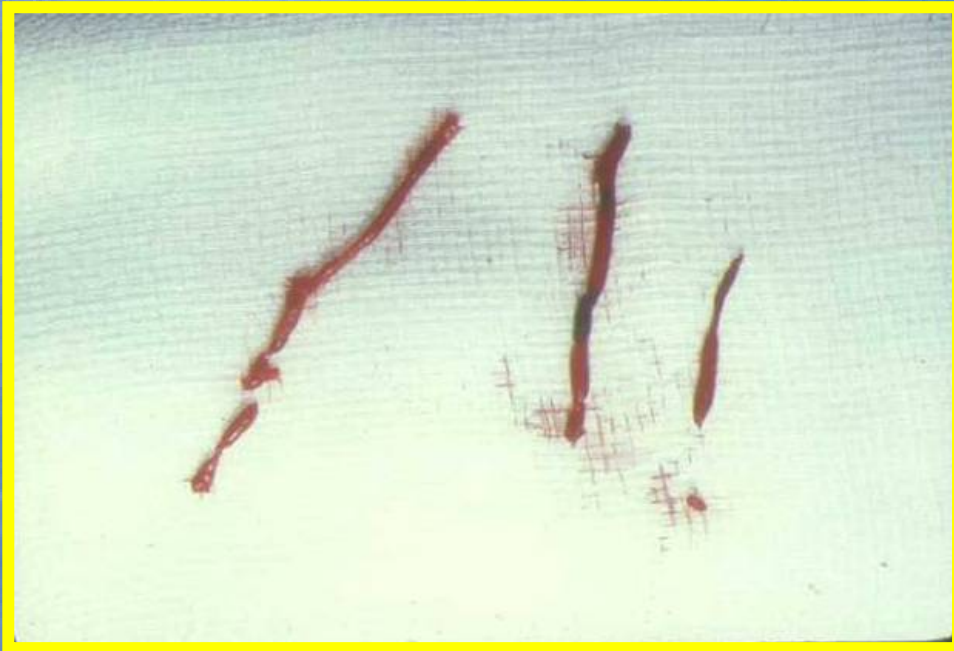- locoregional anesthesia §
tourniquet**
- resection of the ulnar
anevryσμα**



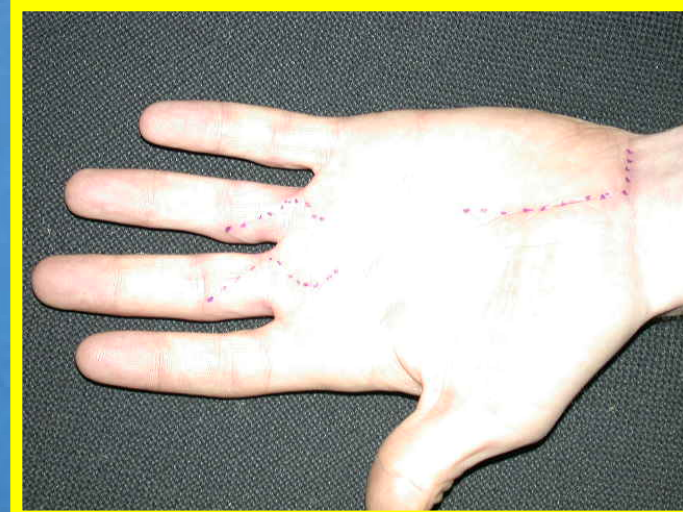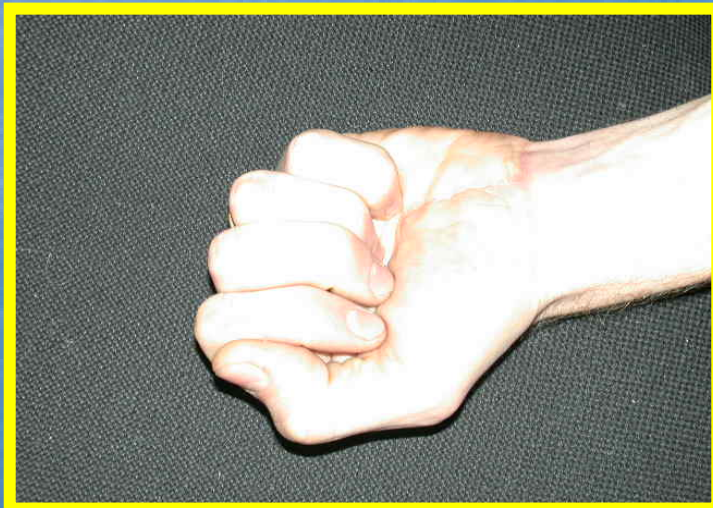
**For both cases :
direct suture of ulnar artery**




**For both cases :
embolectomy of digital
arteries**



**For both cases:
good functional and
aesthetic results**



DISCUSSION



Discussion :

Etiologies of digital ischemia



1. **Acute :**
 - anévrisme
 - embolisation (A.F. tumors, cholestérol, TOS)
 - iatrogenic
2. **Chronic :**
 - artériopathies
 - systemic diseases
 - tumors
 - médications
3. **Both :**
 - A.F. and arteriopathy

Discussion

Material of acute digital ischemia

- 1987-2004 : 32 patients
- 24 M, 8 F
- Average age : 38 years (5-68)
- Etiologies : 15 ulnar aneurisma by microtraumatic injuries (13 M, 2 F)
- 1 radial anévrisma (1 M)
- 2 ulnar aneurisma by direct trauma on the triquetrum (1M, 14 years, skate boart and 1 M, 17 years, roller)
- 13 cardiac auricular fibrillations (5 F, 9 M)
- 1 complication of gunshot injury by embolisation (1 F, 5 years)



CONCLUSIONS

